Management of atherosclerotic extracranial carotid artery stenosis

Leo H Bonati, Olav Jansen, Gert J de Borst, Martin M Brown

Atherosclerosis leading to stenosis of the internal carotid artery is the underlying cause of 8–15% of ischaemic strokes (symptomatic carotid stenosis). 1–2% of the adult population have asymptomatic carotid stenosis. Clinical trials in patients with symptomatic carotid stenosis showed a higher procedural risk of non-disabling stroke with stenting versus endarterectomy, but a higher risk of myocardial infarction, cranial nerve palsy, and access site haematoma with endarterectomy. Apart from procedural complications, both treatments are equally effective in preventing stroke and recurrent severe carotid stenosis in the medium-to-long term. Endarterectomy has a modest effect in preventing stroke among patients with asymptomatic carotid stenosis, whereas the role of stenting remains to be established. With advances in medical therapy against atherosclerosis, benefit from invasive therapy has become uncertain. Risk modelling, with the inclusion of brain and carotid plaque imaging, will become increasingly important in selecting patients for interventions.

Lancet Neurol 2022; 21: 273–83

Department of Neurology and Stroke Center, Department of Clinical Research, University Hospital Basel and University of Basel, Basel, Switzerland (Prof L H Bonati MD); **Clinic for Radiology and Neuroradiology, UKSH Campus Kiel, Kiel, Germany** (Prof O Jansen PhD); **Department of Vascular Surgery, University Medical Center, Utrecht, Netherlands** (Prof G J de Borst MD); **Stroke Research Centre, Department of Brain Repair and Rehabilitation, UCL Queen Square Institute of Neurology, University College London, London, UK** (Prof M M Brown FRCP)

Correspondence to: Prof Martin M Brown, Stroke Research Centre, Department of Brain Repair and Rehabilitation, UCL Queen Square Institute of Neurology, University College London, London, UK **martin.brown@ucl.ac.uk**

Introduction

Atherosclerotic carotid artery disease that narrows the internal carotid artery by 50% or more is found in 15–20% of patients who present with ischaemic stroke or transient ischaemic attack.[1,2] However, in a case series,[1] the stenosis was only considered to have been the underlying cause of the symptoms in 8% of those presenting with ischaemic stroke or transient ischaemic attack. The global prevalence of carotid stenosis is estimated to be 1·8% in men and 1·2% in women aged 30–79 years.[3] The prevalence among men ranged from 0·5% in those aged 30–34 years to 6·9% in those aged 75–79 years, whereas the prevalence among women ranged from 0·3% in those aged 30–34 years to 4·3% in those aged 75–79 years.

Despite a wealth of existing evidence, many concerns about the management of symptomatic and asymptomatic carotid disease remain. Improved medical therapy has lowered atherosclerosis-related morbidity and mortality, raising questions about the benefit of carotid revascularisation in many patients. However, imaging of atherosclerotic plaque morphology beyond measuring the degree of stenosis has improved the identification of patients at risk for stroke, who are more likely to benefit from carotid revascularisation, including some people not previously considered to be at risk. Finally, although the choice between carotid endarterectomy and stenting for symptomatic carotid stenosis is informed by evidence from numerous randomised trials, important technical advances in carotid artery stenting have taken place in the past decade since these trials were performed. The role of stenting in asymptomatic carotid stenosis remains uncertain. There is concern that many patients are receiving carotid revascularisation without good evidence of benefit. Therefore, we considered that a review of the scientific basis of practice in the management of carotid atherosclerosis was timely. In this Review, we discuss the existing evidence on medical and invasive therapy, highlight advances in risk prediction and treatments, and point out areas of remaining uncertainty and ongoing research, providing a basis for individualised treatment decisions now and in the future. Non-atherosclerotic diseases of the carotid artery, such as dissection or fibromuscular dysplasia, and intracranial atherosclerosis will not be covered in this Review.

Pathophysiology

Atherosclerosis mostly occurs at the carotid bifurcation, involving the distal common carotid artery and the proximal internal carotid artery; less often, the origin of the common carotid artery and the cavernous segment of the intracranial carotid artery are involved. The most important mechanism by which carotid stenosis causes stroke or transient ischaemic attack is rupture of the atherosclerotic plaque with subsequent embolism of a locally formed thrombus or plaque debris (figure 1). Inflammation in the plaque has an important role in this process.[4] Other recognised stroke mechanisms include propagation or embolisation of a thrombus from an occluded extracranial internal carotid artery, and haemodynamic impairment (ie, a reduction in cerebral perfusion). Carotid disease has traditionally been inferred as a potential cause for a stroke or transient ischaemic attack in the presence of at least 50% stenosis associated with ipsilateral carotid territory symptoms. However, atherosclerotic plaques with lesser degrees of stenosis might also cause embolic stroke or transient ischaemic attack. Carotid stenosis is commonly defined as symptomatic if it has caused ischaemic events in the ipsilateral eye (transient monocular blindness or amaurosis fugax, or retinal infarction) or cerebral hemisphere (transient ischaemic attack or stroke) in the previous 6 months. Large artery atherosclerosis, when identified as the underlying cause of transient ischaemic attack, incurs the highest risk of early recurrent stroke among all of the causes.[2]

Optimal medical therapy

Optimal medical therapy and lifestyle modification are the basis of effective management of carotid artery

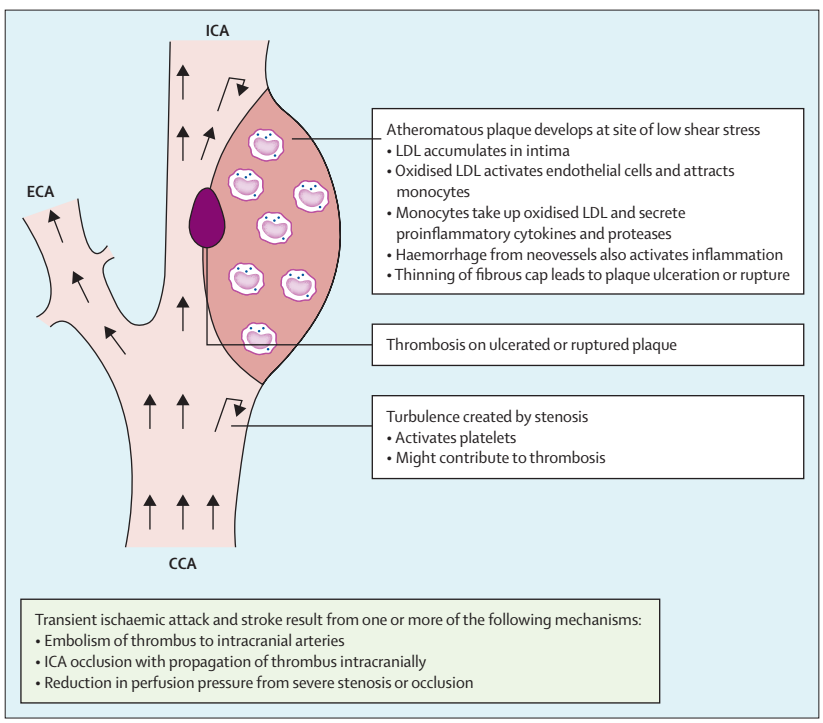

Figure 1: **Pathophysiology of stroke originating from carotid artery stenosis**
CCA=common carotid artery. ECA=external carotid artery. ICA=internal carotid artery.

Panel 1: **Optimal medical management of carotid artery disease**

Antithrombotic therapy
- Asymptomatic carotid stenosis
  - Aspirin, aspirin plus dipyridamole, or clopidogrel[5]
  - Low-dose rivaroxaban (2·5 mg twice daily) plus aspirin[6,7]
- Symptomatic carotid stenosis causing minor stroke or transient ischaemic attack
  - Aspirin plus clopidogrel for 3 weeks to 3 months[8,9]
  - Aspirin plus ticagrelor for 30 days[10]
  - Single antiplatelet therapy thereafter
- Oral anticoagulation if otherwise indicated (eg, in patients with atrial fibrillation)

Lipid-lowering therapy
- Target LDL cholesterol ≤1·4 mmol/L[11] using a healthy diet plus:
  - A statin, with or without ezetimibe
  - Ezetimibe
  - PCSK9 inhibitors

Antihypertensive therapy
- Target blood pressure ≤140/90 mm Hg measured in the clinic or ≤135/85 mm Hg measured at home

Glycaemic control in type 2 diabetes
- Target glycated haemoglobin A_{1c} ≤6·5%

Lifestyle modification
- Smoking cessation
- Weight reduction
- Regular exercise (150 min of moderate aerobic activity per week)

disease and apply to all patients (panel 1). It is reasonable to recommend low-dose aspirin therapy in patients with asymptomatic carotid stenosis, to prevent cardiovascular events as a whole.[5] A combination of low-dose rivaroxaban (2·5 mg twice daily) and aspirin was shown to be superior to aspirin monotherapy for long-term prevention of stroke and other cardiovascular events in patients with stable atherosclerotic disease, including those with asymptomatic carotid stenosis.[6,7]

Patients with symptomatic carotid stenosis causing recent minor stroke or transient ischaemic attack benefit from urgent dual antiplatelet therapy with a combination of aspirin and clopidogrel for 3 weeks to 3 months after the initial event, or aspirin and ticagrelor for 30 days after the initial event, followed by antiplatelet monotherapy.[8–10] Previously, dual antiplatelet therapy with ticagrelor and aspirin has been shown to be more effective in symptomatic large artery atherosclerosis compared with other causes of stroke,[12] although this finding was not the case with clopidogrel and aspirin treatment.[13] Co-existing atrial fibrillation and carotid artery disease has been shown to augment the risk of stroke in study populations without control of medication.[14] However, in the Rivaroxaban Once Daily Oral Direct Factor Xa Inhibition Compared with Vitamin K Antagonism for Prevention of Stroke and Embolism Trial in Atrial Fibrillation (also known as ROCKET AF), comparing rivaroxaban with warfarin in patients with atrial fibrillation, co-existing carotid artery disease did not increase the risk of stroke.[15] Thus, there is no evidence to support the addition of aspirin to oral anticoagulation in patients with atrial fibrillation and concomitant asymptomatic carotid stenosis. However, individual patients with symptomatic carotid stenosis and concomitant atrial fibrillation who have a high risk of developing atheroembolism (eg, evidenced by repetitive ipsilateral emboli clinically or on imaging, or imaging features of plaque instability) might benefit from adding antiplatelet therapy to oral anticoagulation temporarily, to prevent early recurrent stroke before carotid revascularisation.

Guidelines on lipid-lowering therapy by the American College of Cardiology/American Heart Association, and by the European Society of Cardiology/European Atherosclerosis Society, consider both asymptomatic and symptomatic carotid stenosis as manifest atherosclerotic cardiovascular disease, conferring very high cardiovascular risk.[11,16] Among patients with symptomatic carotid stenosis, atherosclerotic cardiovascular disease is already documented by the presence of stroke or transient ischaemic attack. Yet, even the presence of carotid plaque

without symptoms (asymptomatic carotid stenosis) is considered equivalent to atherosclerotic cardiovascular disease in some guidelines.[11] It is unclear if patients with a minor degree of asymptomatic carotid stenosis (<50% narrowing) benefit from aggressive cholesterol lowering in the absence of other cardiovascular disease history, and whether imaging features of plaque instability confer additional benefit from cholesterol-lowering in such patients. Current European guidelines recommend an LDL cholesterol target of 1·4 mmol/L in patients at very high cardiovascular risk, whereas American guidelines recommend high-intensity statins irrespective of serum cholesterol concentrations.[11,16] The PCSK9 inhibitors evolocumab and alirocumab were shown to prevent cardiovascular events among patients with stable atherosclerotic disease by lowering baseline LDL cholesterol by about 60%, in combination with established statin therapy.[17,18] However, current data on PCSK9 inhibitors in patients with carotid artery disease are insufficient.

Blood pressure control in patients with hypertension, glycaemic control in people with diabetes, smoking cessation, and weight reduction are other important elements in the medical management of carotid disease.[19] Most patients with carotid stenosis will tolerate blood pressure lowering. In case of symptoms attributable to haemodynamic impairment with antihypertensive therapy, a higher blood pressure target might be selected in individual patients, based on clinical judgment.

Advances in medical therapy—in particular, widespread use of statins and other agents to achieve low cholesterol concentrations, more strict adherence to blood pressure targets, and improved control of other risk factors—appear to have lowered the risk of stroke in patients with asymptomatic and symptomatic carotid stenosis who have been treated conservatively.[20] The observed 90-day stroke risk after a transient ischaemic attack caused by large artery atherosclerosis declined from 20% in registries conducted more than 15 years ago,[21,22] to 6% in a large registry published in 2016.[2] Although some of this decline might have been accounted for by more rapid specialised assessment and early carotid revascularisation in selected patients, improvement in medical therapy probably also contributed.

Revascularisation for symptomatic carotid stenosis

The benefit of carotid endarterectomy in patients with symptomatic carotid stenosis was established in the final two decades of the past century. In the North American Symptomatic Carotid Endarterectomy Trial (NASCET), the 2-year risk of any ipsilateral stroke (including perioperative events) in patients with severe symptomatic carotid stenosis (≥70% narrowing of the lumen) was reduced from 26% to 9% (p<0·001).[23] Modest benefit was also observed in patients with moderate stenosis (50–69%) by a reduction of stroke risk from 22·2% to 15·7% (p=0·045) after 5 years.[24] In the European Carotid Surgery Trial (ECST),[25] endarterectomy prevented stroke only in patients with symptomatic carotid stenosis of 80% or greater, but measurement of the degree of stenosis on angiography differed between the trials. In a pooled analysis of NASCET, ECST, and the smaller Veterans Affairs trial, in which ECST angiograms were reanalysed using the NASCET method, the absolute 5-year risk reduction from endarterectomy was 15·9% in patients with severe (≥70%) stenosis and 4·6% in patients with moderate (50–69%) stenosis.[26] Thus, six patients with severe symptomatic stenosis, or 22 patients with moderate symptomatic stenosis, had to be operated on to prevent one ipsilateral stroke after 5 years (the number needed to treat). Furthermore, extracranial-intracranial bypass surgery is not effective to prevent stroke in patients with carotid artery occlusion.[27]

Endovascular treatment with stents, usually with access through the femoral artery, is an alternative option. Risks and benefits of carotid stenting versus endarterectomy for symptomatic carotid stenosis have been compared in several randomised trials. The Endarterectomy versus Angioplasty in Patients with Symptomatic Severe Carotid Stenosis (EVA-3S) trial was stopped early after the inclusion of 527 patients, because the procedural (30-day) stroke or death risk in the stenting group exceeded that in the endarterectomy group (9·6% *vs* 3·9%).[28] The Stent-Supported Percutaneous Angioplasty of the Carotid Artery versus Endarterectomy (SPACE) trial, which included 1214 patients, reported similar risks of procedural stroke or death—7·4% in the stenting group and 6·6% in the carotid endarterectomy group—but the trial was unable to prove non-inferiority of stenting according to its design.[29,30] The International Carotid Stenting Study (ICSS), which included 1713 patients, reported a significantly higher risk of procedural stroke or death in the stenting group than in the endarterectomy group (7·4% *vs* 3·4%; risk ratio 2·16, 95% CI 1·40–3·34; p=0·0004) in an interim analysis.[31] Among the 1321 patients with symptomatic carotid stenosis enrolled in the North American Carotid Revascularization Endarterectomy versus Stenting Trial (CREST), procedural stroke or death risks in the stenting group (6·0%) were lower than in the previous trials, but still higher than in the endarterectomy group (3·2%; hazard ratio 1·89, 95% CI 1·11–3·21; p=0·02).[32]

A 2020 update of a Cochrane systematic review and meta-analysis of carotid artery stenting versus endarterectomy[33] included data from eight trials, including the aforementioned large trials.[28,30–32] Analysis of a total of 5184 patients with symptomatic carotid stenosis showed an average risk of procedural stroke or death of 7·3% with stenting and 4·4% with endarterectomy, resulting in a random-effects odds ratio (OR) of 1·74 (95% CI 1·30–2·33; p=0·0002), favouring endarterectomy in the overall population included in the trials.[33]

Panel 2: **Ongoing randomised trials of carotid revascularisation**

Second Asymptomatic Carotid Surgery Trial (trial registration ISRCTN21144362)
Stenting versus endarterectomy for asymptomatic carotid stenosis; recruitment of 3625 patients from 2008 to 2020, follow-up ongoing; 130 study sites in 33 countries

Second European Carotid Surgery Trial (trial registration ISRCTN97744893)
Revascularisation versus optimised medical therapy alone for asymptomatic or low-to-intermediate risk symptomatic carotid stenosis; recruitment of 429 patients from 2012 to 2019, follow-up ongoing; 23 study sites in Europe and Canada

Carotid Revascularisation and Medical Management for Asymptomatic Carotid Stenosis Trial (trial registration NCT02089217)
Two parallel trials: carotid artery stenting versus best medical therapy alone, and carotid endarterectomy versus best medical therapy alone, for asymptomatic carotid stenosis; recruitment ongoing since 2014, target population 2480 patients; 157 study sites in the USA, Canada, Israel, and Spain

Endarterectomy Combined With Optimal Medical Therapy (OMT) versus OMT Alone in Patients With Asymptomatic Severe Atherosclerotic Carotid Artery Stenosis at Higher-than-average Risk of Ipsilateral Stroke (trial registration NCT02841098)
Endarterectomy versus optimal medical therapy alone in patients with asymptomatic carotid stenosis and presence of imaging features associated with increased stroke risk; recruitment ongoing since 2019, target population 700 patients; 23 study sites in France

Revascularisation for asymptomatic carotid stenosis

In patients with asymptomatic carotid stenosis of 60% or higher, carotid endarterectomy consistently reduced the cumulative 5-year stroke risk from about 11% with medical therapy to about 6% in the Asymptomatic Carotid Atherosclerosis Study[34] and the Asymptomatic Carotid Surgery Trial (ACST),[35] resulting in a number needed to treat of 20 to prevent one stroke in 5 years.

Among the 1181 patients with asymptomatic carotid stenosis enrolled in CREST, there was no significant difference in the risk of procedural stroke or death between stenting and endarterectomy (2·5% *vs* 1·4%).[32] The Asymptomatic Carotid Trial 1 (ACT-1), which included 1453 patients, reported procedural stroke or death risks of 2·9% in the stenting group and 1·7% in the endarterectomy group, a difference which was not statistically significant.[36] The report of the initial results of the Second Asymptomatic Carotid Surgery Trial (ACST-2) in August, 2021, in which 3625 patients with asymptomatic carotid stenosis were recruited, more than doubled the evidence on stenting versus endarterectomy for asymptomatic carotid stenosis.[37] The risk of procedural stroke or death was 3·7% in the stenting group and 2·7% in the endarterectomy group, and the risks of procedural disabling stroke or death were 0·9% in the stenting group and 1·0% in the endarterectomy group. Generally, postprocedural stroke risks did not significantly differ between stenting and endarterectomy in these trials.

Reductions in stroke risk under modern medical therapy might obviate the need for revascularisation in many patients with asymptomatic carotid stenosis,[38] and possibly also among some patients with symptomatic carotid stenosis. However, the procedure-related risks of carotid revascularisation have also declined.[39] This decline in stroke risk has led to several ongoing trials investigating the current benefit of carotid revascularisation versus medical therapy alone in the context of optimal medical therapy (panel 2).

Technical aspects of revascularisation

A randomised trial showed no significant difference in procedural risks of endarterectomy performed under local anaesthesia compared with general anaesthesia,[40] whereas in real-world conditions, local anaesthesia appears to be safer.[41]

Around two-thirds of procedural strokes counted within 30 days of carotid stenting occur on the day of the procedure, mostly at the time of stent deployment or post-stent balloon dilation.[42] Passage of the stenosis with the catheter, shortening of self-expanding stents after deployment, and compressing the struts of the stent against the atheromatous plaque during balloon dilatation might dislodge plaque debris or local thrombus. Cerebral protection devices were therefore developed with the aim of preventing cerebral embolisation during carotid stenting. A pooled analysis of the EVA-3S, SPACE, and ICSS trials showed no significant difference in procedural stroke or death risk between stenting with use of a protection device (mostly of the filter type) and unprotected stenting.[43] Although filter-type protection devices might capture some emboli during stent deployment, it is possible that crossing the stenosis with the device before the filter is deployed might also dislodge thrombus material from the plaque. A different approach to cerebral protection involves flow reversal during the procedure using devices placed proximal to the stenosis, which has been shown to prevent some emboli compared with distal filter devices.[44,45]

Another possible cause of stroke during catheterisation using the standard access route is dislodgement of thrombus or plaque debris from atherosclerosis of the aortic arch and proximal access vasculature, particularly among patients with difficult vascular anatomy.[46] To avoid navigating the aortic arch, direct puncture of the common carotid artery with previous surgical incision (transcarotid

artery revascularisation [TCAR]) has been tested, with relatively low risks of periprocedural stroke or death in prospective single-arm studies;[47–49] these findings were subsequently supported in larger registries.[50–52] However, TCAR has mostly been used in either patients who are asymptomatic or those who are symptomatic and at low risk for recurrent stroke.[53] The value of TCAR in patients with symptomatic carotid stenosis has yet to be proven. Transbrachial access also avoids aortic arch-related complications.[54]

The design of carotid stents also affects procedural risk. So-called closed-cell stents (in which the open area between stent struts is ≤5·0 mm² and all stent struts are interconnected) are associated with a lower risk of periprocedural stroke or death than an open-cell design.[43,55] The tight meshes of closed-cell stents might be better suited to sealing off the atherosclerotic plaque and prevent appositional thrombus at the surface of the plaque or plaque debris escaping into the blood stream during the procedure. This concept has sparked the development of multi-layered stents with very small open areas.[56,57]

Other procedure-related complications

Cerebral embolism during carotid revascularisation might occur without overt clinical symptoms. In a substudy of 231 patients in ICSS,[58] 62 (50%) of 124 in the stenting group and 18 (17%) of 107 in the endarterectomy group had new ischaemic brain lesions on diffusion-weighted MRI after the procedure (OR 5·21, 95% CI 2·78–9·79; p<0·0001). 68 (85%) of 80 patients with new ischaemic lesions did not have any associated symptoms. Silent infarcts on MRI might serve as surrogate outcome measures for the procedural safety of carotid revascularisation.[59]

Procedure-related clinical manifestations of myocardial infarction are rare compared with stroke, occurring in 0·3% to 0·5% of individuals with stenting and in 0·6% to 0·9% of individuals with endarterectomy.[28,31,36,37] The incidence was highest in the CREST trial,[32] in which patients were routinely screened with enzyme measurement and electrocardiography before and after treatment, and myocardial infarction was defined by an increase in serum levels of cardiac enzymes together with either typical chest pain or changes on electrocardiogram consistent with myocardial ischaemia. The risks of periprocedural biochemical myocardial infarction according to this definition were 1·1% in the carotid stenting group and 2·3% in the carotid endarterectomy group. 15 (36%) of 42 periprocedural myocardial infarctions occurring in the CREST study population as a whole were asymptomatic.[60]

Cranial nerve injury occurred in 5·6% of patients treated with endarterectomy versus 0·4% of patients treated with stenting in a systematic review of randomised controlled trials.[33] Cranial nerve palsies usually result from surgical traction on the nerve and the majority are temporary; only a very small proportion remain permanent. Panel 3 summarises the procedural and post-procedural complications of carotid revascularisation.

Panel 3: Main procedural and postprocedural complications of carotid revascularisation

Procedural complications (≤30 days)
- Intraoperative stroke
- Postoperative stroke
- Death
- Myocardial infarction
- Postendarterectomy hypotension
- Postendarterectomy hypertension
- Cerebral hyperperfusion syndrome
- Bleeding or wound haematoma
- Cranial nerve injury
- Silent cerebral ischaemic lesions
- Wound infection
- Internal carotid artery occlusion
- Residual stenosis
- Allergic reactions to contrast medium

Postprocedural complications (>30 days)
- Restenosis
- Patch infection
- Pseudoaneurysm

Long-term durability of treatment

Stroke prevention

Clinical trials have consistently showed that, among patients with symptomatic carotid stenosis, long-term rates of recurrent stroke (excluding procedure-related events) were remarkably low after revascularisation and did not significantly differ between endarterectomy and stenting.[30,61–63] In ICSS, for example, 5-year ipsilateral stroke risks were 4·7% in the stenting group and 3·4% in the endarterectomy group.[62] Among patients with symptomatic carotid stenosis included in the CREST trial, the 10-year rates of ipsilateral stroke were 6·9% in the stenting group and 5·6% in the endarterectomy group.[63] In a pooled analysis of the four largest trials comparing stenting versus endarterectomy for symptomatic carotid stenosis, annual risk of post-procedural ipsilateral stroke was 0·6% in both treatment groups.[64]

In CREST, postprocedural event rates were identical among patients with symptomatic and asymptomatic carotid stenosis and did not significantly differ between stenting and endarterectomy, suggesting that initial symptom status is relevant for the risk of procedural stroke, but not for the long-term risk of recurrent stroke after revascularisation.[63] Similarly, long-term stroke rates did not significantly differ between stenting and endarterectomy among patients with asymptomatic carotid stenosis in the ACT-1 and the ACST-2 trials.[36,37] In ACST-2, postoperative stroke rates were very low, with a

reported cumulative 5-year risk of ipsilateral fatal or disabling stroke of 0·6% in both groups, and of ipsilateral stroke of any severity of 2·1% in the stenting group and 1·0% in the endarterectomy group.[37]

Restenosis

Evidence on recurrent stenosis after treatment is available from follow-up of patients with duplex ultrasound at regular intervals in randomised controlled trials.[61–63] Although ultrasound criteria differed, most of these trials reported no significant difference in the occurrence of severe restenosis or occlusion between stenting and endarterectomy in the long term, with cumulative risks 5 years to 10 years after treatment ranging from 5% to 12% in the stenting group and from 8% to 10% in the endarterectomy group. Moderate or greater restenosis (≥50%), however, is more common and occurred more often in stent-treated patients.[61,65]

Restenosis typically occurs in the first 1–2 years after carotid revascularisation and is most often caused by neointimal hyperplasia, a proliferation of smooth muscle cells that appears to be less prone to cause thromboembolic events than recurrent atherosclerosis.[66] Nonetheless, there is some evidence that carotid artery restenosis increases the risk of stroke.[67] This increase in stroke risk appears to be more pronounced with restenosis after endarterectomy than with restenosis after stenting,[65,68] hinting at possible differences in pathogenesis. However, the annual risk of stroke in patients with severe restenosis after treatment of symptomatic carotid stenosis is only about 1%, which is roughly the same as expected in a patient with severe asymptomatic carotid stenosis not undergoing revascularisation who is receiving treatment with current medical therapy (as recommended in panel 1).[65]

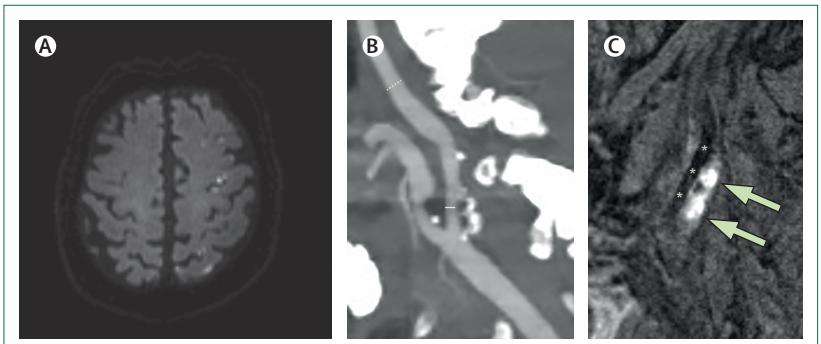

Figure 2: **Role of carotid plaque MRI in a patient with symptomatic carotid artery stenosis**
Example of a patient with recurrent left-hemispheric transient ischaemic attacks. (A) Diffusion-weighted MRI shows multiple embolic lesions in the vascular border zone between the left middle and anterior cerebral arteries. (B) CT angiography shows a mixed calcified and soft plaque at the origin of the left internal carotid artery causing 40% narrowing of the lumen according to the method of measuring stenosis used in the North American Symptomatic Carotid Endarterectomy Trial;[23] hereby the diameter at the site of maximum narrowing (straight line) is compared with the diameter of the distal, non-diseased artery where the walls run parallel (dashed line). (C) The magnetisation-prepared rapid acquisition with gradient echo sequence of plaque MRI shows increased signal in the carotid plaque, signifying intra-plaque haemorrhage (arrows). The lumen of the internal carotid artery appears dark (asterisks). This patient is at increased risk of stroke and might benefit from carotid revascularisation despite the stenosis measuring <50%.

Selection of patients and procedures

Prediction of stroke risk with medical therapy alone

Estimation of the risk of stroke with medical therapy is key to selecting patients who are likely to benefit from revascularisation of carotid stenosis, particularly in light of emerging evidence that stroke risks have declined both for symptomatic and asymptomatic carotid stenosis with advances in medical management of atherosclerotic disease.[2,20–22] A clinical model that estimated the risk of ipsilateral stroke from carotid stenosis treated with medical therapy alone was originally derived using data from patients included in the control (avoid surgery) group of ECST and validated using data from NASCET.[69] This model estimated the 5-year risk of ipsilateral stroke in a patient with symptomatic carotid stenosis based on sex, age, degree of stenosis, type of and time since the presenting ischaemic event, plaque surface irregularity or ulceration on catheter angiography, as well as vascular risk factors and comorbidities. Applying the model to data from the NASCET trial showed that only patients with a predicted 5-year stroke risk of more than 20% could be expected to have a clear benefit from surgery. A recalibrated model was used to select patients for the second ECST, which tests the hypothesis whether modern medical therapy alone obviates the need for carotid revascularisation among patients with symptomatic or asymptomatic carotid stenosis with a predicted 5-year stroke risk of less than 20% (panel 2).

Several prospective observational studies showed that certain imaging features of the carotid plaque are associated with an increased risk for future cerebrovascular events.[70] For patients with symptomatic carotid stenosis, the best evidence is currently available for the presence of haemorrhage visualised in carotid plaques on MRI using specialised MR sequences. Patients with recently symptomatic carotid stenosis and intraplaque haemorrhage seen on MRI face an 11-fold increase in risk of ipsilateral stroke, even after adjustment for previously identified clinical risk factors, including degree of stenosis.[71] Importantly, the risk of recurrent stroke is also increased among patients with intraplaque haemorrhage causing less than 50% stenosis, many of whom would have previously been considered to have cryptogenic stroke or stroke of uncertain origin, and who are not currently considered candidates for carotid revascularisation (figure 2). PET can be used to visualise plaque inflammation-related metabolism by uptake of ^{18}F-fluorodeoxyglucose, which has been shown to predict early recurrent stroke among patients with recently symptomatic carotid stenosis.[72,73]

For patients with asymptomatic carotid stenosis, a number of features on duplex ultrasound have been associated with increased risk of cerebrovascular events, including degree and progression of stenosis,[74–78] echolucent plaque,[79] and in particular echolucent areas near the surface of the plaque.[80] Additionally, the presence of microembolic signals detected by transcranial Doppler

ultrasound in the middle cerebral artery ipsilateral to an asymptomatic carotid stenosis increases the risk of stroke about six-fold.[81] Reduced cerebrovascular reserve distal to severe symptomatic or asymptomatic carotid stenosis assessed by transcranial Doppler ultrasound also increases the risk for cerebrovascular events.[82,83] The 2017 European Society for Vascular Surgery (ESVS) guidelines recommend consideration of revascularisation in patients with asymptomatic carotid stenosis only if one or more imaging or clinical features associated with increased risk of stroke are present.[5] However, the value of these investigations in selecting patients has not been shown in the context of a clinical trial and, outside of research studies, few clinicians currently use plaque imaging to select patients for revascularisation. We anticipate that this practise will change in the future.

Selection for carotid stenting or endarterectomy

Combining randomised data from several trials allows adequately powered subgroup analyses to investigate if the relative effect of stenting versus endarterectomy differs between patient groups. A pooled analysis of individual patient data from four major trials within the Carotid Stenosis Trialists' Collaboration comparing the two treatments in patients with symptomatic carotid stenosis showed that the risk of procedural stroke or death strongly increases with age in patients treated with stents, but this finding was not the case with endarterectomy.[84,85] By contrast, age had surprisingly little effect on the risk of stroke occurring beyond the procedural period.[85] The reasons why higher age increases procedure-related stroke risk in carotid stenting are not completely clear; more difficult vascular anatomy, increased burden of atherosclerosis in the aortic arch and supra-aortic arteries, more unstable plaques,[86] or less capacity to compensate for periprocedural embolism at higher age are possible mechanisms. The 2017 ESVS guidelines, as well as the 2021 guidelines by the European Stroke Organisation (ESO), therefore advise against stenting in patients with symptomatic carotid stenosis who are older than 70 years, except in specific conditions when surgery is not feasible, or the risk of complications with surgery is deemed high.[5,87] In patients younger than 70 years, carotid stenting is a suitable option to offer patients provided no other contraindications to stenting are present.

Anatomical features of supra-aortic arteries might also increase the risk of stroke during stenting. For example, angulation in the course of the stenotic internal carotid artery by 60° or higher quadrupled the risk of periprocedural brain infarction in the ICSS-MRI substudy, but had no significant effect on the risk of endarterectomy.[46]

Timing of revascularisation in patients with symptomatic carotid stenosis

An individual patient data meta-analysis of randomised controlled trials clearly showed that the benefit of carotid endarterectomy in patients with symptomatic carotid stenosis was most pronounced among those who were included within 2 weeks of the index neurological event.[88] In patients with severe (70–99%) stenosis, benefit was still present at up to 12 weeks; by contrast, among patients with a moderate degree of stenosis (50–69%), the benefit of surgery was no longer present after 14 days. Although some evidence suggests increased procedure-related risks for urgent carotid endarterectomy performed within 2 days of the presenting event,[89] early surgery thereafter is safe, including for suitable patients initially treated with thrombolysis for acute stroke.[90,91] Despite advances in medical therapy, there is still a considerable risk of early recurrent stroke in patients with symptomatic carotid stenosis awaiting revascularisation.[92] The 2017 ESVS and the 2021 ESO guidelines therefore recommend operating on patients with symptomatic carotid stenosis who are deemed to require revascularisation as soon as possible, preferably within 14 days of the first ischaemic event.[5,87]

A pooled-analysis by the Carotid Stenosis Trialists' Collaboration also yielded some evidence that the extra risk of periprocedural stroke or death associated with stenting versus endarterectomy in patients with symptomatic carotid stenosis is increased when treating patients within the first week after the symptomatic event.[93] It is possible that in the first days after an initial event plaques are particularly unstable and vulnerable to periprocedural thromboembolic complications. The effects of age and timing of intervention are supported by trial evidence dating back from more than 10 years ago and might be less pronounced in the current era, owing to advances in stent and catheter technology, medication (combined antiplatelet therapy), and increased experience with stenting. Panel 4 summarises current indications for endarterectomy and stenting in patients with symptomatic and asymptomatic carotid stenosis according to current guidelines.[5,87]

Revascularisation in patients at high surgical risk

Stenting might be the preferred option if revascularisation of the carotid artery is warranted in individual patients with a stenosis at a surgically inaccessible site, or in patients with stenosis after previous cervical irradiation therapy, in whom the risk for transient cranial nerve palsy after endarterectomy is increased.[94] Patients having repeat surgery for restenosis after previous endarterectomy are at increased risk for wound and patch infection and, hence, might also be better candidates for stenting.

Stenting might also have advantages over endarterectomy in patients who are at increased risk for cardiovascular complications with surgery. The Stenting and Angioplasty with Protection in Patients at High Risk for Endarterectomy (SAPPHIRE) trial included 334 patients with concomitant cardiopulmonary disease, contralateral carotid occlusion, stenosis occurring after neck irradiation or previous endarterectomy, or other criteria thought to increase surgical risk.[95] In these

Panel 4: Indications for carotid endarterectomy and stenting*

Symptomatic carotid stenosis

- Carotid endarterectomy
  - Recommended for severe stenosis (70–99%)
  - Suggested for moderate stenosis (50–69%)
  - Not recommended for minor stenosis (<50%)
  - Recommended within 14 days of the first ischaemic event
- Carotid artery stenting
  - Suggested as an alternative to endarterectomy in patients <70 years old
  - Not recommended in patients with severe atherosclerosis of the aortic arch or tortuosity of supra-aortic vessels

Asymptomatic carotid stenosis

- Carotid endarterectomy
  - Recommended for 60–99% stenosis in patients at increased stroke risk
- Carotid artery stenting
  - Not routinely recommended
  - Possible option in selected patients unsuitable for surgery, provided they benefit from revascularisation

*Recommendations for carotid endarterectomy and stenting, according to current guidelines.[5,87]

Search strategy and selection criteria

We searched databases, including MEDLINE, Science Citation Index, and the Cochrane Central Register of Controlled Trials, up to Aug 31, 2021. An English language search was done using the terms ("carotid stenosis" OR "carotid artery disease") AND ("prevalence" OR "age" OR "sex" OR "stroke" OR "transient ischaemic attack" OR "transient monocular blindness" OR "amaurosis fugax" OR "aspirin" OR "clopidogrel" OR "ticagrelor" OR "anticoagulation" OR "lipid lowering therapy" OR "stenting" OR "embolism" OR "protection devices" OR "flow reversal" OR "stent design" OR "trans-carotid" OR "endarterectomy" OR "anaesthesia" OR "randomised controlled trials" OR "patient selection" OR "magnetic resonance imaging" OR "positron emission tomography" OR "ultrasound"). We selected studies with a randomised trial design and systematic reviews thereof, large observational registries, and reports of technical developments in carotid revascularisation. The final reference list was generated on the basis of relevance to the topics covered in this Review.

patients, stenting was non-inferior to surgery with regard to the primary composite outcome of death, stroke, or myocardial infarction within 30 days after the intervention, or death or ipsilateral stroke between 31 days and 1 year,[95] and no significant difference was seen in ipsilateral stroke risk up to 3 years after treatment.[96] Notably, more than 70% of patients in the SAPPHIRE trial had asymptomatic carotid stenosis. In patients with asymptomatic carotid stenosis and severe cardiopulmonary disease, most clinicians would opt for conservative therapy.

Conclusions and future directions

Atherosclerotic stenosis of the internal carotid artery, which is typically located at the site of the carotid bifurcation at the neck, is a common cause of ischaemic stroke. Early trials reported a substantial reduction in stroke risk with carotid endarterectomy in patients with severe symptomatic carotid stenosis, and a modest benefit in patients with moderate symptomatic stenosis, as well as in patients with asymptomatic carotid stenosis. Advances in medical therapy for atherosclerosis and improved risk factor control might have diminished the benefit of surgery. Identification of patients at increased risk of stroke while receiving medical therapy, particularly among those with moderate symptomatic or asymptomatic stenosis, is essential to improve selection of the optimal strategy for long-term stroke prevention. Imaging of carotid plaque composition using MRI and other modalities will probably have an increasingly important role in patient selection.

Among patients with symptomatic carotid stenosis, randomised controlled trials have consistently shown that the risk of periprocedural stroke or death is greater with stenting than with endarterectomy. However, this outcome was mainly caused by a higher risk of minor stroke occurring with stenting, and the extra events largely occurred in patients older than 70 years. Conversely, stenting reduces the risk of procedure-related myocardial infarction, cranial nerve palsy, and haematoma at the access site. Excluding periprocedural events, stenting and endarterectomy work equally well to prevent recurrent stroke or recurrence of stenosis. For patients in whom both stenting and endarterectomy are feasible (ie, symptomatic carotid stenosis), the choice of treatment should primarily be based on an assessment of procedural risks. Additionally, stenting might be considered in symptomatic patients at increased risk for complications with surgery, people in whom the stenosis occurred after previous surgery or after radiation therapy to the neck, and if the stenosis is not surgically accessible, provided these individuals are considered to benefit from revascularisation. Stenting should not be routinely used to treat asymptomatic carotid stenosis, but might be suggested in asymptomatic patients in whom revascularisation is considered to be appropriate and who are less suitable for surgery.[87]

Future research should be directed at improving the selection of patients with carotid stenosis who are at risk of stroke and benefit from revascularisation, based on risk models enriched with imaging data. New trials are needed to show if the recent technological advances in carotid artery stenting have improved procedural safety

to the level achieved with endarterectomy. Finally, emerging antithrombotic and lipid-lowering medications might further reduce the overall risk of stroke and other vascular events in patients with carotid disease.

Contributors

LHB performed the literature review and wrote the first draft of the manuscript. OJ, GJdB, and MMB contributed to the editing of the text. MMB initiated the Review and takes final responsibility for the content. All authors contributed to editing and commenting on the text.

Declaration of interests

LHB has received grants from Swiss National Science Foundation, University of Basel, Swiss Heart Foundation, and AstraZeneca; personal fees from Amgen, Bayer, Bristol-Myers Squibb, Claret Medical, and InnovHeart; and non-financial support from AstraZeneca and Bayer. OJ has received personal fees from Acandis. The other authors declare no competing interests.

References

1 Cheng SF, Brown MM, Simister RJ, Richards T. Contemporary prevalence of carotid stenosis in patients presenting with ischaemic stroke. *Br J Surg* 2019; **106:** 872–78.

2 Amarenco P, Lavallée PC, Labreuche J, et al. One-year risk of stroke after transient ischemic attack or minor stroke. *N Engl J Med* 2016; **374:** 1533–42.

3 Song P, Fang Z, Wang H, et al. Global and regional prevalence, burden, and risk factors for carotid atherosclerosis: a systematic review, meta-analysis, and modelling study. *Lancet Glob Health* 2020; **8:** e721–29.

4 Ross R. Atherosclerosis—an inflammatory disease. *N Engl J Med* 1999; **340:** 115–26.

5 Naylor AR, Ricco JB, de Borst GJ, et al. Editor's choice—management of atherosclerotic carotid and vertebral artery disease: 2017 Clinical Practice Guidelines of the European Society for Vascular Surgery (ESVS). *Eur J Vasc Endovasc Surg* 2018; **55:** 3–81.

6 Eikelboom JW, Connolly SJ, Bosch J, et al. Rivaroxaban with or without aspirin in stable cardiovascular disease. *N Engl J Med* 2017; **377:** 1319–30.

7 Anand SS, Bosch J, Eikelboom JW, et al. Rivaroxaban with or without aspirin in patients with stable peripheral or carotid artery disease: an international, randomised, double-blind, placebo-controlled trial. *Lancet* 2018; **391:** 219–29.

8 Wang Y, Wang Y, Zhao X, et al. Clopidogrel with aspirin in acute minor stroke or transient ischemic attack. *N Engl J Med* 2013; **369:** 11–19.

9 Johnston SC, Easton JD, Farrant M, et al. Clopidogrel and aspirin in acute ischemic stroke and high-risk TIA. *N Engl J Med* 2018; **379:** 215–25.

10 Johnston SC, Amarenco P, Denison H, et al. Ticagrelor and aspirin or aspirin alone in acute ischemic stroke or TIA. *N Engl J Med* 2020; **383:** 207–17.

11 Mach F, Baigent C, Catapano AL, et al. 2019 ESC/EAS guidelines for the management of dyslipidaemias: lipid modification to reduce cardiovascular risk. *Eur Heart J* 2020; **41:** 111–88.

12 Amarenco P, Denison H, Evans SR, et al. Ticagrelor added to aspirin in acute nonsevere ischemic stroke or transient ischemic attack of atherosclerotic origin. *Stroke* 2020; **51:** 3504–13.

13 Yaghi S, de Havenon A, Rostanski S, et al. Carotid stenosis and recurrent ischemic stroke: a post-hoc analysis of the POINT Trial. *Stroke* 2021; **52:** 2414–17.

14 Bunch TJ, Bair TL, Crandall BG, et al. Stroke and dementia risk in patients with and without atrial fibrillation and carotid arterial disease. *Heart Rhythm* 2020; **17:** 20–26.

15 Kochar A, Hellkamp AS, Lokhnygina Y, et al. Efficacy and safety of rivaroxaban compared with warfarin in patients with carotid artery disease and nonvalvular atrial fibrillation: insights from the ROCKET AF trial. *Clin Cardiol* 2018; **41:** 39–45.

16 Stone NJ, Robinson JG, Lichtenstein AH, et al. 2013 ACC/AHA guideline on the treatment of blood cholesterol to reduce atherosclerotic cardiovascular risk in adults: a report of the American College of Cardiology/American Heart Association Task Force on Practice Guidelines. *Circulation* 2014; **129** (suppl 2)**:** S1–45.

17 Sabatine MS, Giugliano RP, Keech AC, et al. Evolocumab and clinical outcomes in patients with cardiovascular disease. *N Engl J Med* 2017; **376:** 1713–22.

18 Schwartz GG, Steg PG, Szarek M, et al. Alirocumab and cardiovascular outcomes after acute coronary syndrome. *N Engl J Med* 2018; **379:** 2097–107.

19 NICE. Hypertension in adults: diagnosis and management. 2019. https://www.nice.org.uk/guidance/ng136 (accessed Dec 17, 2021).

20 Marquardt L, Geraghty OC, Mehta Z, Rothwell PM. Low risk of ipsilateral stroke in patients with asymptomatic carotid stenosis on best medical treatment: a prospective, population-based study. *Stroke* 2010; **41:** e11–17.

21 Lovett JK, Coull AJ, Rothwell PM. Early risk of recurrence by subtype of ischemic stroke in population-based incidence studies. *Neurology* 2004; **62:** 569–73.

22 Purroy F, Montaner J, Molina CA, Delgado P, Ribo M, Alvarez-Sabín J. Patterns and predictors of early risk of recurrence after transient ischemic attack with respect to etiologic subtypes. *Stroke* 2007; **38:** 3225–29.

23 North American Symptomatic Carotid Endarterectomy Trial Collaborators. Beneficial effect of carotid endarterectomy in symptomatic patients with high-grade carotid stenosis. *N Engl J Med* 1991; **325:** 445–53.

24 Barnett HJ, Taylor DW, Eliasziw M, et al. Benefit of carotid endarterectomy in patients with symptomatic moderate or severe stenosis. *N Engl J Med* 1998; **339:** 1415–25.

25 European Carotid Surgery Trialists Collaborative Group. Randomised trial of endarterectomy for recently symptomatic carotid stenosis: final results of the MRC European Carotid Surgery Trial (ECST). *Lancet* 1998; **351:** 1379–87.

26 Rothwell PM, Eliasziw M, Gutnikov SA, et al. Analysis of pooled data from the randomised controlled trials of endarterectomy for symptomatic carotid stenosis. *Lancet* 2003; **361:** 107–16.

27 Powers WJ, Clarke WR, Grubb RL Jr, et al. Extracranial-intracranial bypass surgery for stroke prevention in hemodynamic cerebral ischemia: the Carotid Occlusion Surgery Study randomized trial. *JAMA* 2011; **306:** 1983–92.

28 Mas JL, Chatellier G, Beyssen B, et al. Endarterectomy versus stenting in patients with symptomatic severe carotid stenosis. *N Engl J Med* 2006; **355:** 1660–71.

29 Ringleb PA, Allenberg J, Brückmann H, et al. 30 day results from the SPACE trial of stent-protected angioplasty versus carotid endarterectomy in symptomatic patients: a randomised non-inferiority trial. *Lancet* 2006; **368:** 1239–47.

30 Eckstein HH, Ringleb P, Allenberg JR, et al. Results of the Stent-Protected Angioplasty versus Carotid Endarterectomy (SPACE) study to treat symptomatic stenoses at 2 years: a multinational, prospective, randomised trial. *Lancet Neurol* 2008; **7:** 893–902.

31 Ederle J, Dobson J, Featherstone RL, et al. Carotid artery stenting compared with endarterectomy in patients with symptomatic carotid stenosis (International Carotid Stenting Study): an interim analysis of a randomised controlled trial. *Lancet* 2010; **375:** 985–97.

32 Brott TG, Hobson RW 2nd, Howard G, et al. Stenting versus endarterectomy for treatment of carotid-artery stenosis. *N Engl J Med* 2010; **363:** 11–23.

33 Müller MD, Lyrer P, Brown MM, Bonati LH. Carotid artery stenting versus endarterectomy for treatment of carotid artery stenosis. *Cochrane Database Syst Rev* 2020; **2:** CD000515.

34 Walker MD. Endarterectomy for asymptomatic carotid artery stenosis. Executive Committee for the Asymptomatic Carotid Atherosclerosis Study. *JAMA* 1995; **273:** 1421–28.

35 Halliday A, Mansfield A, Marro J, et al. Prevention of disabling and fatal strokes by successful carotid endarterectomy in patients without recent neurological symptoms: randomised controlled trial. *Lancet* 2004; **363:** 1491–502.

36 Rosenfield K, Matsumura JS, Chaturvedi S, et al. Randomized trial of stent versus surgery for asymptomatic carotid stenosis. *N Engl J Med* 2016; **374:** 1011–20.

37 Halliday A, Bulbulia R, Bonati LH, et al. Second asymptomatic carotid surgery trial (ACST-2): a randomised comparison of carotid artery stenting versus carotid endarterectomy. *Lancet* 2021; **398:** 1065–73.

38 Keyhani S, Cheng EM, Hoggatt KJ, et al. Comparative effectiveness of carotid endarterectomy vs initial medical therapy in patients with asymptomatic carotid stenosis. *JAMA Neurol* 2020; **77:** 1110–21.

39 Müller MD, von Felten S, Algra A, et al. Secular trends in procedural stroke or death risks of stenting versus endarterectomy for symptomatic carotid stenosis. *Circ Cardiovasc Interv* 2019; **12:** e007870.

40 Vaniyapong T, Chongruksut W, Rerkasem K. Local versus general anaesthesia for carotid endarterectomy. *Cochrane Database Syst Rev* 2013; **12:** CD000126.

41 Knappich C, Kuehnl A, Tsantilas P, et al. Intraoperative completion studies, local anesthesia, and antiplatelet medication are associated with lower risk in carotid endarterectomy. *Stroke* 2017; **48:** 955–62.

42 Müller MD, von Felten S, Algra A, et al. Immediate and delayed procedural stroke or death in stenting versus endarterectomy for symptomatic carotid stenosis. *Stroke* 2018; **49:** 2715–22.

43 Wodarg F, Turner EL, Dobson J, et al. Influence of stent design and use of protection devices on outcome of carotid artery stenting: a pooled analysis of individual patient data. *J Neurointerv Surg* 2018; **10:** 1149–54.

44 Nikas D, Reith W, Schmidt A, et al. Prospective, multicenter European study of the GORE flow reversal system for providing neuroprotection during carotid artery stenting. *Catheter Cardiovasc Interv* 2012; **80:** 1060–68.

45 Bijuklic K, Wandler A, Hazizi F, Schofer J. The PROFI study (prevention of cerebral embolization by proximal balloon occlusion compared to filter protection during carotid artery stenting): a prospective randomized trial. *J Am Coll Cardiol* 2012; **59:** 1383–89.

46 Müller MD, Ahlhelm FJ, von Hessling A, et al. Vascular anatomy predicts the risk of cerebral ischemia in patients randomized to carotid stenting versus endarterectomy. *Stroke* 2017; **48:** 1285–92.

47 Kwolek CJ, Jaff MR, Leal JI, et al. Results of the ROADSTER multicenter trial of transcarotid stenting with dynamic flow reversal. *J Vasc Surg* 2015; **62:** 1227–34.

48 Plessers M, Van Herzeele I, Hemelsoet D, et al. Transcervical carotid stenting with dynamic flow reversal demonstrates embolization rates comparable to carotid endarterectomy. *J Endovasc Ther* 2016; **23:** 249–54.

49 Pinter L, Ribo M, Loh C, et al. Safety and feasibility of a novel transcervical access neuroprotection system for carotid artery stenting in the PROOF Study. *J Vasc Surg* 2011; **54:** 1317–23.

50 Paraskevas KI, Antonopoulos CN, Kakisis JD, Geroulakos G. An updated systematic review and meta-analysis of results of transcervical carotid artery stenting with flow reversal. *J Vasc Surg* 2020; **72:** 1489–98.

51 Malas MB, Dakour-Aridi H, Wang GJ, et al. Transcarotid artery revascularization versus transfemoral carotid artery stenting in the Society for Vascular Surgery Vascular Quality Initiative. *J Vasc Surg* 2019; **69:** 92–103.

52 Malas MB, Elsayed N, Naazie I, Dakour-Aridi H, Yei KS, Schermerhorn ML. Propensity score-matched analysis of 1-year outcomes of transcarotid revascularization with dynamic flow reversal, carotid endarterectomy, and transfemoral carotid artery stenting. *J Vasc Surg* 2022; **75:** 213–22.

53 Coelho A, Prassaparo T, Mansilha A, Kappelle J, Naylor R, de Borst GJ. Critical appraisal on the quality of reporting on safety and efficacy of transcarotid artery stenting with flow reversal. *Stroke* 2020; **51:** 2863–71.

54 Kühn AL, Singh J, Moholkar VM, et al. Distal radial artery (snuffbox) access for carotid artery stenting - Technical pearls and procedural set-up. *Interv Neuroradiol* 2021; **27:** 241–48.

55 Doig D, Turner EL, Dobson J, et al. Predictors of stroke, myocardial infarction or death within 30 days of carotid artery stenting: results from the international carotid stenting study. *Eur J Vasc Endovasc Surg* 2016; **51:** 327–34.

56 Speziale F, Capoccia L, Sirignano P, et al. Thirty-day results from prospective multi-specialty evaluation of carotid artery stenting using the CGuard MicroNet-covered Embolic Prevention System in real-world multicentre clinical practice: the IRON-Guard study. EuroIntervention 2018; **13:** 1714–20.

57 Broussalis E, Griessenauer C, Mutzenbach S, et al. Reduction of cerebral DWI lesion burden after carotid artery stenting using the CASPER stent system. *J Neurointerv Surg* 2019; **11:** 62–67.

58 Bonati LH, Jongen LM, Haller S, et al. New ischaemic brain lesions on MRI after stenting or endarterectomy for symptomatic carotid stenosis: a substudy of the International Carotid Stenting Study (ICSS). *Lancet Neurol* 2010; **9:** 353–62.

59 Traenka C, Engelter ST, Brown MM, Dobson J, Frost C, Bonati LH. Silent brain infarcts on diffusion-weighted imaging after carotid revascularisation: a surrogate outcome measure for procedural stroke? A systematic review and meta-analysis. *Eur Stroke J* 2019; **4:** 127–43.

60 Blackshear JL, Cutlip DE, Roubin GS, et al. Myocardial infarction after carotid stenting and endarterectomy: results from the carotid revascularization endarterectomy versus stenting trial. *Circulation* 2011; **123:** 2571–78.

61 Mas JL, Arquizan C, Calvet D, et al. Long-term follow-up study of endarterectomy versus angioplasty in patients with symptomatic severe carotid stenosis trial. *Stroke* 2014; **45:** 2750–56.

62 Bonati LH, Dobson J, Featherstone RL, et al. Long-term outcomes after stenting versus endarterectomy for treatment of symptomatic carotid stenosis: the International Carotid Stenting Study (ICSS) randomised trial. *Lancet* 2015; **385:** 529–38.

63 Brott TG, Howard G, Roubin GS, et al. Long-term results of stenting versus endarterectomy for carotid-artery stenosis. *N Engl J Med* 2016; **374:** 1021–31.

64 Brott TG, Calvet D, Howard G, et al. Long-term outcomes of stenting and endarterectomy for symptomatic carotid stenosis: a preplanned pooled analysis of individual patient data. *Lancet Neurol* 2019; **18:** 348–56.

65 Bonati LH, Gregson J, Dobson J, et al. Restenosis and risk of stroke after stenting or endarterectomy for symptomatic carotid stenosis in the International Carotid Stenting Study (ICSS): secondary analysis of a randomised trial. *Lancet Neurol* 2018; **17:** 587–96.

66 De Borst GJ, Moll F. Biology and treatment of recurrent carotid stenosis. *J Cardiovasc Surg (Torino)* 2012; **53** (suppl 1)**:** 27–34.

67 Lal BK, Beach KW, Roubin GS, et al. Restenosis after carotid artery stenting and endarterectomy: a secondary analysis of CREST, a randomised controlled trial. *Lancet Neurol* 2012; **11:** 755–63.

68 Kumar R, Batchelder A, Saratzis A, et al. Restenosis after carotid interventions and its relationship with recurrent ipsilateral stroke: a systematic review and meta-analysis. *Eur J Vasc Endovasc Surg* 2017; **53:** 766–75.

69 Rothwell PM, Mehta Z, Howard SC, Gutnikov SA, Warlow CP. Treating individuals 3: from subgroups to individuals: general principles and the example of carotid endarterectomy. *Lancet* 2005; **365:** 256–65.

70 Saba L, Saam T, Jäger HR, et al. Imaging biomarkers of vulnerable carotid plaques for stroke risk prediction and their potential clinical implications. *Lancet Neurol* 2019; **18:** 559–72.

71 Schindler A, Schinner R, Altaf N, et al. Prediction of stroke risk by detection of hemorrhage in carotid plaques: meta-analysis of individual patient data. *JACC Cardiovasc Imaging* 2020; **13:** 395–406.

72 Marnane M, Merwick A, Sheehan OC, et al. Carotid plaque inflammation on 18F-fluorodeoxyglucose positron emission tomography predicts early stroke recurrence. *Ann Neurol* 2012; **71:** 709–18.

73 Kelly PJ, Camps-Renom P, Giannotti N, et al. carotid plaque inflammation imaged by ^{18}F-fluorodeoxyglucose positron emission tomography and risk of early recurrent stroke. *Stroke* 2019; **50:** 1766–73.

74 Nicolaides AN, Kakkos SK, Griffin M, et al. Severity of asymptomatic carotid stenosis and risk of ipsilateral hemispheric ischaemic events: results from the ACSRS study. *Eur J Vasc Endovasc Surg* 2005; **30:** 275–84.

75 Silvestrini M, Altamura C, Cerqua R, et al. Ultrasonographic markers of vascular risk in patients with asymptomatic carotid stenosis. *J Cereb Blood Flow Metab* 2013; **33:** 619–24.

76 Kakkos SK, Nicolaides AN, Charalambous I, et al. Predictors and clinical significance of progression or regression of asymptomatic carotid stenosis. *J Vasc Surg* 2014; **59:** 956–67.

77 Hirt LS. Progression rate and ipsilateral neurological events in asymptomatic carotid stenosis. *Stroke* 2014; **45:** 702–06.

78 Howard DPJ, Gaziano L, Rothwell PM. Risk of stroke in relation to degree of asymptomatic carotid stenosis: a population-based cohort study, systematic review, and meta-analysis. *Lancet Neurol* 2021; **20:** 193–202.

79 Gupta A, Kesavabhotla K, Baradaran H, et al. Plaque echolucency and stroke risk in asymptomatic carotid stenosis: a systematic review and meta-analysis. *Stroke* 2015; **46:** 91–97.

80 Kakkos SK, Griffin MB, Nicolaides AN, et al. The size of juxtaluminal hypoechoic area in ultrasound images of asymptomatic carotid plaques predicts the occurrence of stroke. *J Vasc Surg* 2013; **57:** 609–18.

81 Markus HS, King A, Shipley M, et al. Asymptomatic embolisation for prediction of stroke in the Asymptomatic Carotid Emboli Study (ACES): a prospective observational study. *Lancet Neurol* 2010; **9:** 663–71.

82 Silvestrini M, Vernieri F, Pasqualetti P, et al. Impaired cerebral vasoreactivity and risk of stroke in patients with asymptomatic carotid artery stenosis. *JAMA* 2000; **283:** 2122–27.

83 Reinhard M, Schwarzer G, Briel M, et al. Cerebrovascular reactivity predicts stroke in high-grade carotid artery disease. *Neurology* 2014; **83:** 1424–31.

84 Bonati LH, Dobson J, Algra A, et al. Short-term outcome after stenting versus endarterectomy for symptomatic carotid stenosis: a preplanned meta-analysis of individual patient data. *Lancet* 2010; **376:** 1062–73.

85 Howard G, Roubin GS, Jansen O, et al. Association between age and risk of stroke or death from carotid endarterectomy and carotid stenting: a meta-analysis of pooled patient data from four randomised trials. *Lancet* 2016; **387:** 1305–11.

86 van Lammeren GW, Reichmann BL, Moll FL, et al. Atherosclerotic plaque vulnerability as an explanation for the increased risk of stroke in elderly undergoing carotid artery stenting. *Stroke* 2011; **42:** 2550–55.

87 Bonati LH, Kakkos S, Berkefeld J, et al. European Stroke Organisation guideline on endarterectomy and stenting for carotid artery stenosis. *Eur Stroke J* 2021; **6:** I–XLVII.

88 Rothwell P, Eliasziw M, Gutnikov SA, et al. Sex difference in the effect of time from symptoms to surgery on benefit from carotid endarterectomy for transient ischemic attack and nondisabling stroke. *Stroke* 2004; **35:** 2855–61.

89 Strömberg S, Gelin J, Osterberg T, Bergström GM, Karlström L, Osterberg K. Very urgent carotid endarterectomy confers increased procedural risk. *Stroke* 2012; **43:** 1331–35.

90 Koraen-Smith L, Troëng T, Björck M, et al. Urgent carotid surgery and stenting may be safe after systemic thrombolysis for stroke. *Stroke* 2014; **45:** 776–80.

91 Brinster CJ, Sternbergh WC 3rd. Safety of urgent carotid endarterectomy following thrombolysis. *J Cardiovasc Surg (Torino)* 2020; **61:** 149–58.

92 Johansson E, Cuadrado-Godia E, Hayden D, et al. Recurrent stroke in symptomatic carotid stenosis awaiting revascularization: a pooled analysis. *Neurology* 2016; **86:** 498–504.

93 Rantner B, Kollerits B, Roubin GS, et al. Early endarterectomy carries a lower procedural risk than early stenting in patients with symptomatic stenosis of the internal carotid artery: results from 4 randomized controlled trials. *Stroke* 2017; **48:** 1580–87.

94 Fokkema M, den Hartog AG, Bots ML, van der Tweel I, Moll FL, de Borst GJ. Stenting versus surgery in patients with carotid stenosis after previous cervical radiation therapy: systematic review and meta-analysis. *Stroke* 2012; **43:** 793–801.

95 Yadav JS, Wholey MH, Kuntz RE, et al. Protected carotid-artery stenting versus endarterectomy in high-risk patients. *N Engl J Med* 2004; **351:** 1493–501.

96 Gurm HS, Yadav JS, Fayad P, et al. Long-term results of carotid stenting versus endarterectomy in high-risk patients. *N Engl J Med* 2008; **358:** 1572–79.

Copyright © 2022 Elsevier Ltd. All rights reserved.